

# Clinical Outcomes in Implant-Supported Full-Arch Fixed Prosthesis Utilizing Pressed Composite Restorations

SORIN GHEORGHE MIHALI<sup>1\*</sup>, EMANUEL ADRIAN BRATU<sup>2</sup>

<sup>1</sup>Victor Babes University of Medicine and Pharmacy, Faculty of Dentistry, Department of Prosthodontics, 2 Eftimie Murgu Sq., 300041, Timisoara, Romania.

<sup>2</sup>Victor Babes University of Medicine and Pharmacy, Faculty of Dentistry, Department of Implant Supported Restorations, 2 Eftimie Murgu Sq., 300041, Timisoara, Romania.

*The author wants to evaluate the clinical advantages and limitations of the composite pressed on metal framework for full-arch implant-supported fixed prosthesis in comparing with dental ceramic restorations. A total of thirty-two edentulous arches were restored. All complications were recorded at each follow-up visit up to 1 year after insertion. No complications were reported on pressed composite restoration. Complications were found in the ceramic restorations like chipping or fracture of the ceramic veneer. The composite pressed restorations are a treatment option for full arch restorations over implants, showing a better success rate in the present study in comparing with ceramic restorations.*

*Keywords:* screw-retained implants restorations, pressed composite restorations, clinical outcomes, edentulous

Treatment of the total edentulous patient can be a real challenge for the clinician. Dental implants have been utilized with a high degree of success to solve functional difficulties associated with edentulous jaws; they can offer to the patient what almost every patient would prefer the opportunity of having a fixed reconstruction [1]. The implant-supported fixed dental restorations can be screw-retained or cement-retained. The type of retention for these restorations remains an important decision factor for the clinician due to the advantages and limitations of both screw- and cement-retained restorations [2, 3]. The decision of which type of restoration should be used is largely determined by the experience of the clinician and clinical aspects. The patients are not showing any preference for either retention system, but despite this, there are some relevant clinical and technical differences between the two types of restorative connections [4]. The screw-retained restorations can be removed whenever the clinician considers is applicable, and gives the patient the opportunity to a better hygiene. The presence of suppuration, fistula, the peri-implantitis due to the impossibility (inability) to remove all the cement, are some of the outcomes of the cement-retained restorations [5].

Fixed dental implant restorations can be fabricated from many combinations of materials such as metal alloy-acrylic, metal alloy-composite, and metal alloy-ceramic. There is extensive evidence of the excellent long-term result from conventional metal-ceramic and metal-resin implant-supported fixed dental prostheses [6-8]. Conventionally metal-ceramic restorations have the drawback of difficulty in fitting when full-arch implant-supported restorations are required, wear of opposing surfaces, ceramic chipping, difficulty in shade matching of acrylic and pink ceramic and extensive work for repair after framework breakage have encouraged dentists to look for other material options. Metal-acrylic restorations have more disadvantage by accelerated wear and loss of sheen, including fractured or debonded acrylic resin teeth, which can adversely impact esthetics. In recent years, fixed dental restorations based on yttria-stabilized tetragonal zirconia polycrystals (Y-TZP)

have increased popularity due to their excellent biocompatibility and good esthetics. On the ZrO<sub>2</sub> was reported a minimally framework fracture; however, veneering porcelain fracture and chipping has been more commonly reported [9]. Due to the disadvantages of the ceramic materials listed above, there is a need to improve restorations featuring a lifelike and esthetic appearance by means of predictable, fast and high-quality manufacturing processes. The highlights are: precise results as the wax-up is directly converted into the final composite restoration: easy reproducibility and fast repair options; Material and time savings due to the efficient veneering of small and large restorations. Micro-opal fillers ensure the esthetic and lifelike appearance of the completed restorations, which deliver durable shade stability and gloss.

The use of composite resin for framework-supported is an option that has been proposed. It can be used for veneering restorations using the layering technique or injected and pressed. The structure and composition of a new generation of composites is the fillers and monomers. The microfiller is a highly dispersed silicon dioxide with particles in the 10 to 50 nm range and with a large surface area of up to 400m<sup>2</sup>/g (fig. 1 a). The main filling component (62.9%) is a prepolymer/copolymer which consists of pre-polymerised ground up UDMA matrix and inorganic microfiller particles (fig. 1 b). This combination of microfillers plus *microfilled* prepolymer enables a very high filling ratio and excellent physical properties. As the prepolymer is UDMA based it possesses similar characteristics to the main matrix and on polymerisation becomes completely integrated into the overall composite. The result is a homogenous composite with a high loading of inorganic microfillers. The use of the prepolymer allows the advantages of large filler particles to be combined with those of microfillers. This technology allows a higher strength of composite than if only inorganic microfillers were used. The matrix consists of aromatic aliphatic urethane dimethacrylate and decandiol dimethacrylate/aliphatic dimethacrylate. Aliphatic refers to the carbon

\*email:sorin.mihali@dentalexperts.ro Phone:+40744546768





The master cast and opposing cast was articulated using the determination of clinical interocclusal relationship with temporary acrylic resin restoration. One silicon index was also created after temporary or wax-up model. According to the corresponding implant type by using silicon index the metal framework was designed. The framework was sufficiently reduced to prevent shadow areas and to achieve an esthetically natural looking of soft-tissue. After some minor adjustments the framework was blasted with aluminum oxide ( $Al_2O_3$ , 80 – 100 $\mu$ m) at 2 bar pressure. Sandblasting improves the mechanical bond because it roughens the surface and therefore substantially increases the surface of the alloy. Before application of the opaquer, SR Link bonding agent was applied to the areas to be veneered using a clean disposable brush and allowed to react for 3 minutes. Next, the first opaque layer, depending on the desired color was applied thinly using the ready-to-use opaque paste. It is essential that the opaque lay is applied in a homogeneous coating and that the retention beads and veneering areas are completely leveled and/or covered. This is all the more important because the opaque presents the most important bond between the metal and composite. It must be mentioned that at this step it is not necessary to apply the macro-retention layer. Using SR Nexco Flask, the metal framework can be veneered. The wax-up or diagnostic model similar with temporary restorations was duplicated, so the opposing mould is formed. For this step is used transparent silicone (Transil F, Ivoclar Vivadent, Liechtenstein) because pressed composite needs light transmission to the material, same like the classic one. The first layer of dentine composite (SR Nexco, Ivoclar Vivadent, Liechtenstein) is injected into this matrix, under pressure to remove the formed bubbles (if there are any), then using light-curing; the required time is depending on the manufactures. Application of the layer of effects is necessary for a high degree of aesthetics. The fabricated silicon index was provided for the cut-back procedure. After this step sand-blasted with aluminum oxide is needed, also the steamer (by using too much time the steamer on the restoration can cause the contraction). A specially detensioning liquid is applied after which is introduced into an ultrasonic bath of distilled water. Direct contact with the restoration is forbidden. With the forceps on the restoration was applied the chemical bond primer. Normally, the restoration is now prepared for injecting the next layer, and then the following steps are similar as the dentine layer. Polishing and finishing was made with the rotary instruments at turation under 25000 rpm. Because this type of pressed composite restoration is chosen in order to restore a full arch with subdimension vertical occlusion, it is necessary to apply the layer gingiva, which is made respecting the same steps that we used for the steps of dentin and incisal layers.

The final full arch prostheses were clinically verified with one screw test for passive fit. Moreover, radiographs were taken for radiographic examination. All patients approved and agreed with shape and shade of finals restorations (fig. 5).

The screw-retained restorations were fixed to the implant and the torque was 25 N/cm. Teflon was placed in all access holes. A light-cure composite was used as a conventional sealing for pressed composite restoration and metal-ceramic restorations. For full ceramic restoration a ceramic inlay destined to close the access hole [11]. This ceramic piece should offer an excellent marginal fit and should have the same color as the screwed restoration (fig. 6).

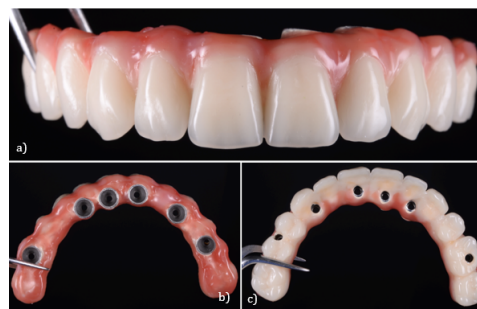

Fig. 5. Implant screw-retained Full-Arch Fixed Pressed Composite Prosthesis: a – frontal view; b – intra view; c – occlusal view.

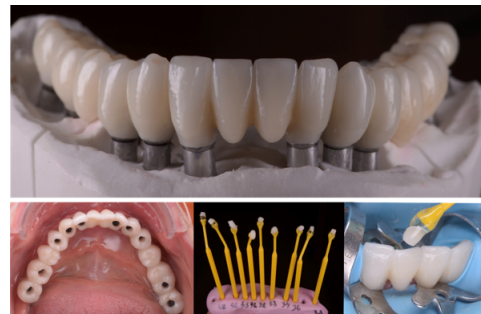

Fig. 6. Ceramic with Zirconia frameworks for full arch implant supported reconstructions

On the day of delivery, alginate impressions were made to fabricate full-cover maxillary night guards. A week later, patients received the night guards and were instructed to wear them at night. Recall appointments were performed after 3, 6, 12 months after insertion. All appointment is required for clinical and radiographic examination.

## Results and discussions

Twenty patients received implant prosthesis with pressed composites for full arch reconstructions. Four implants were placed in 2 arches, 6 arches received six implants, 18 arches received eight implants, and 6 arches received ten implants. No implant failures or complications were reported for an implant survival rate of 100%.

All thirty-two full arches were implant supported screw-retained restorations. Twenty full arch restorations were composite pressed on metal. Nine full arch restorations were Zirconia framework designed and veneering with porcelain. Three of the implant-supported prosthesis was metal-ceramic restorations. All prostheses were in function at the time of the follow-up up to 1 year. All Implant-Supported Full-Arch Fixed Prosthesis was clinically and radiographically examined. No defects of the prosthesis were detected and no frameworks needed to be remade. Chipping fracture of the ceramic veneer occurred in 10 of 12 ceramic restorations (fig. 7), giving a prosthetic success rate of 76%. Chip-off fracture occurred in the occlusal and buccal surface of the ceramic veneers layers in metal-ceramic and zirconia ceramic restorations (fig.8). A feldspathic ceramic veneers was used to restore the chipping. No fracture of the metal or zirconia frameworks or any other mechanical complications such as screw loosening or decementation of the prostheses were reported. No patient complaints regarding their prosthesis esthetic or function were recorded on pressed composite restoration (fig. 9). On the other hand more complications were found in the ceramic restorations (Table 1) that required repair by laboratory technicians or correction of clinicians such as chipping of veneers.

The fabrication of an implant-supported reconstruction includes many clinical and laboratory processes and a series of decisions related to the use of implant

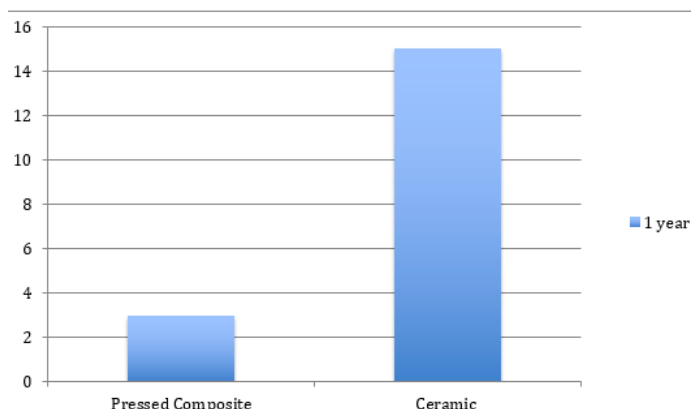


Fig. 7. Comparison in complication between Ceramic Implant-Supported Full-Arch Restoration and Pressed Composite Implant-Supported Full-Arch Prosthesis after 1 year of function.

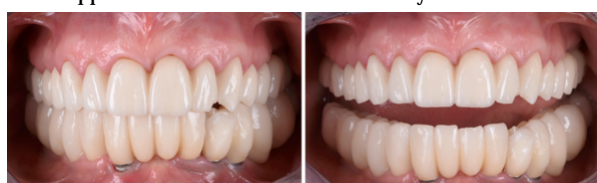

Fig. 8. Chipping fracture occurred in the occlusal and buccal surface of the ceramic restorations.

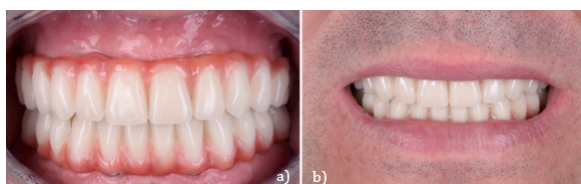


Fig. 9. Intraoral frontal (a) and smile view (b) of the final Pressed Composites Prostheses on metal framework.

components, materials, etc. The treating clinician and the technician must select the method of retention, screw or cemented. Both methods have their advantages and limitations [12]. A major problem of cement retention is the difficulty of removing excess cement [13], which has been associated with the development of peri-implant diseases such as peri-implant mucositis and peri-implantitis [14]. The full arch filler press restorations used in the study group were only screw-retained, so peri-implantitis and peri-implant mucositis hasn't been registered. The screw-retained implant reconstructions are easy to remove during hygiene maintenance or repairs [15]. These are some of reasons why we choose this type of retention. There are listed the outcomes of the classical composite, such as microleakage, rapid wear, bacterial infiltration, discoloration, etc. Also, the composites are not capable of providing color stability [16].

But in our study group, the filler press composite that we use in the full-arch reconstructions different than the

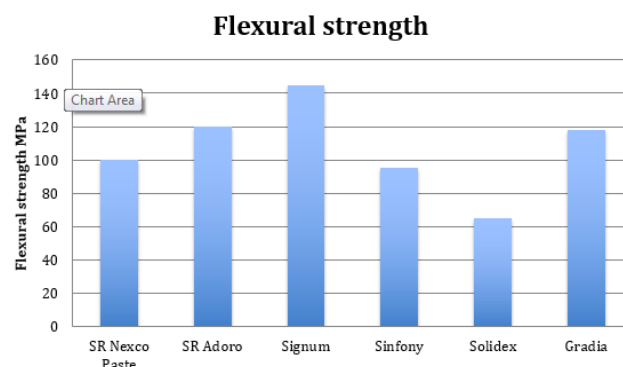


Fig. 10. Comparison of flexural strength in various lab composites (incisal materials). (R&D Ivoclar Vivadent)

common composite. Nano-ceramic ceramic particle reinforced composite were created by incorporating  $Al_2O_3$  ceramic particles into the surface of AA6061-T6 alloy plate with multiple pass friction stir processing [17]. Based on its high flexural strength and high fatigue resistance, this material is ideal for challenging cases like implant supported crowns [18]. We agree with this study, because we also observed that this filler-press resin doesn't show the outcomes of the conventional composite. It is more resistant; the degree of abrasion was similar to ceramic restorations. Also, the restorations in our study group maintained its color in comparison with the control group with conventional composite restorations.

Technical complications of all ceramic and metal-ceramic restorations are found to be frequent, including veneering material chipping/fracture, framework fracture and fracture of the opposing restoration [19]. In our study group we didn't registered any mechanical problems like chipping or fracturing of any composite pressed restoration. In the control group we noticed a higher number of chipping and ceramic fracture, especially to those with both arches restored with ceramic material. The filler press composite is a material much more elastic than ceramic, but at the same time, a very strong one, due the ceramic nanoparticles in its composition.

One of in vitro investigations form the basis for all material tests during the development phase of a dental product the flexural strength of SR Nexco Paste (Ivoclar Vivadent, Liechtenstein) compared to five other composites, (SR Adoro/ Ivoclar Vivadent, Signum/Heraeus, Gradia/GC, Solidex/Shofu and Sinfony/3M ESPE) was tested according to EN ISO 10477 [20]. The dimensions of the test samples were 2 x 2 x 25 mm and all were polymerised in devices compliant with the stipulations of the respective manufacturer. The flexural strength exhibited by SR Nexco Paste was far higher than the EN ISO 10477 stipulation of 50 MPa (fig. 10). The clinical result of our study mention that we don't have any complication in fracturing or chipping by veneering the metal framework with SR Nexco (Ivoclar Vivadent, Liechtenstein).

Table 1

EVALUATION OF CLINICAL RESULTS OF 20 CASES IN WHICH PRESSED COMPOSITE, METAL-CERAMIC RESTORATION AND ZIRCONIA FRAMEWORK FOR FULL ARCH IMPLANT SUPPORTED RECONSTRUCTION WAS USED.

Location	Composite pressed on metal			Ceramic-Zirconia			Metal-ceramic		
	Complications	Number of implants	Time of follow-up	Complications	Number of implants	Time of follow-up	Complications	Number of implants	Time of follow-up
Mandible	none	53	1 year	Chipping #3	30	1 year	Chipping #3	15	1 year
Maxilla	none	95	1 year	Chipping #4	35	1 year	none	20	1 year

Although using monolithic zirconia CAD-/CAM-milled framework fixed dental prostheses in the implant-based rehabilitations of edentulous patients is another treatment option. Some of the benefits are the accuracy, reduced veneering porcelain, and minimal occlusal adjustments [21] but a chip-off fracture of the ceramic veneer occurred in 1 of 26 restorations giving a prosthetic success rate of 96%. In our clinical study a success rate with zirconia ceramic restorations was less than 76%, maybe despite veneering the framework with ceramic and not using monolithic one. A systematic review [22] of complete-arch implant-supported monolithic zirconia fixed dental prostheses shows that Complete-arch dental implant restoration with monolithic zirconia is associated with high short-term success. Despite the many advantages and short-term favorable reports, studies of longer duration are necessary to validate the broad application of this therapy.

## Conclusions

A dental pressed composite, with a metal framework structure are a treatment option for full arch restorations over implants, showing a better success rate in the present study when comparing with ceramic restorations. Some of the benefits are force absorbing, implant bone reabsorption, and minimal occlusal adjustments. A full occlusal contour of composite can diminish chipping of the veneered porcelain. Screw-retained implant restorations due to their retrievability, less biological complications, and easy repair of technical complications. The outcome of the present study showed high success in function, aesthetics, phonetics, and high patient satisfaction.

*Acknowledgements:* This work was supported in part by a project grant, number: P III-C5-TC-2017-03-ERPOCSI.

## References

1. ADELL, R., LEKHOLM, U., ROCKLER, B., BRÄNEMARK, PI., Int J Oral Surg., 10, no. 6, 1981, p. 387-416.
2. SHADID, R., SADAQUA, N., Journal of Oral Implantology 38, 2012, p. 298-307.

3. LEE, A., OKAYASU, K., WANG, H. L., Implant Dentistry 19, 2010, p. 8-15.
4. WITTNEBEN, JG., MILLEN, C., BRA GGER, U., Int J Oral Maxillofac Implants., no. 29, 2014, p. 84-98.
5. SAILER, I., MUHLEMANN, S., ZWAHLEN, M., HAMMERLE, C. H., SCHNEIDER, D., Clin Oral Implants Res. 23, 2012 p. 163-201.
6. PJETURSSON, BE., SAILER, I., MAKAROV, NA., ZWAHLEN, M., THOMA, DS., Dent Mater 6, no. 31, 2015, p. 624-39.
7. PJETURSSON, BE., TAN, K., LANG, NP., BRAGGER, U., EGGER, M., ZWAHLEN, M., Clin Oral Implants Res., 6, no.15, 2004 p. 667-76.
8. ÖRTORP, A., JEMT, T., Clin Implant Dent Relat Res., 1, no. 14, 2012, p. 88-99.
9. PAPASPYRIDAKOS, P., LAL, K., Clin Oral Implants Res., 6, no. 24, 2013, p. 659-65.
10. BRATU, E., MIHALI, S., SHAPIRA, L., BRATU, DC., WANG, HL., Int J Oral Maxillofac Implants., 2, No. 30, 2015, p: 435-40.
11. MIHALI S, CANJAU S, BRATU E, WANG HL. Int J Oral Maxillofac Implants., 5, no. 31, 2016, p. 1142-9.
12. SHADID R, SADAQA N., J Oral Implantol., 3, no. 38, 2012, p. 298-307.
13. LINKEVICIUS T, VINDASIUTE E, PUISYS A, LINKEVICIENE L, MASLOVA N, PURIENE A., Clin Oral Implants Res., 1, no. 24, 2013, p. 71-76.
14. WADHWANI C1, RAPOPORT D, LA ROSA S, HESS T, KRETSCHMAR S., J Prosthet Dent., 3, no.107, 2012, p. 151-7.
15. MICHALAKIS KX, HIRAYAMA H, GAREFIS PD., Int J Oral Maxillofac Implants., 5, no.18, 2003, p.719-28.
16. PINTO GDA C, DIAS KC, CRUVINEL DR, GARCIA LDA F, CONSANSI, PIRES-DE-SOUZA FDE C., Indian J Dent Res., 3, no.24, 2013, p.363-8.
17. MIN YANG, CHENGYING XU, CHUANSONG WU, KUO-CHI LIN, YUH J. CHAO, LINAN AN. J Mater Sci, 45, 2010, p. 4431-4438.
18. MIHALI S., BORTUN C., BRATU E., Rev. Chim.(Bucharest), 64, no.4, 2013, p. 435
19. BOZINI T, PETRIDIS H, GAREFIS K, GAREFIS P, Int J Oral Maxillofac Implants. 26, no. 2, 2011, p.304-18.
20. GAWDZINSKA K., NABIALEK M., BRYLL K., SZYMANSKI P, SANDU A.V. Mat. Plast., 54, no.3, 2017, p. 539
21. CARAMES, J, TOVAR SUINAGA, L, YU YC, PEREZ A, KANG M., Int J Dent., 6, no. 1, 2015, p. 392-496.
22. ABDULMAJEED AA., LIM KG., NARHI TO., COOPER LF., J Prosthet Dent., 115, no. 6, 2016, p. 672-677.

Manuscript received:6.05.2017